

QUIZ CASES

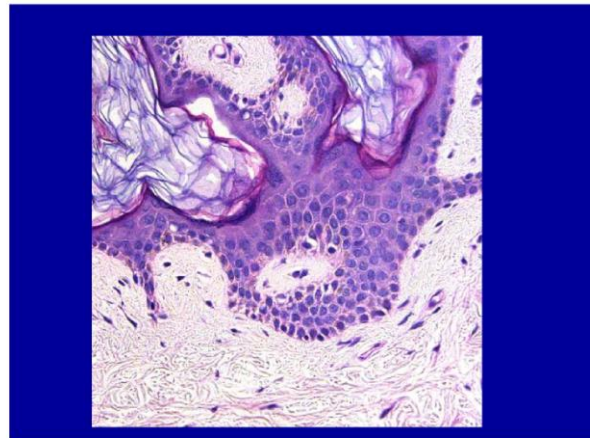
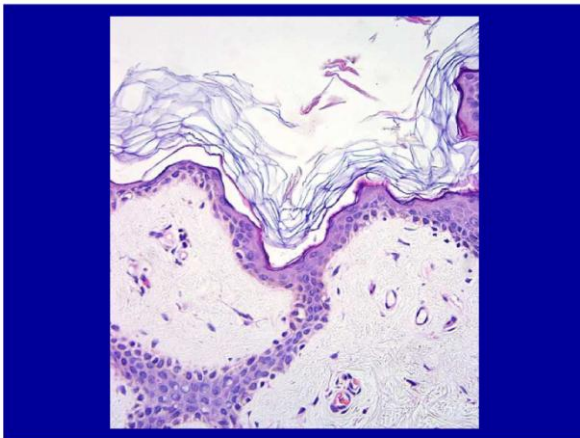
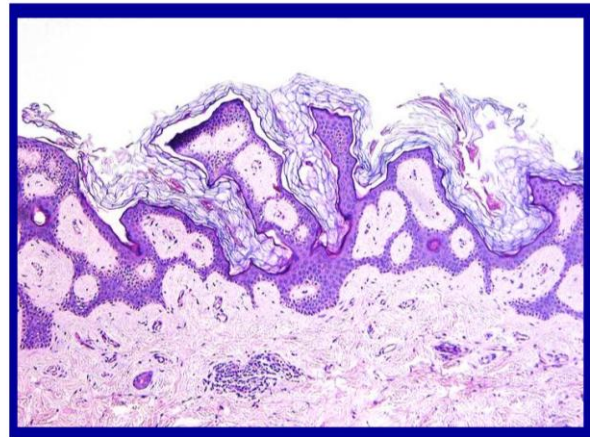
Zsolt B. Argenyi

Department of Pathology  
University of Washington, Seattle, WA

CASE NO. 17

Biopsy taken from a brown, scaly patch on the chest. The patient is a 29 year-old woman. The most appropriate diagnosis is:

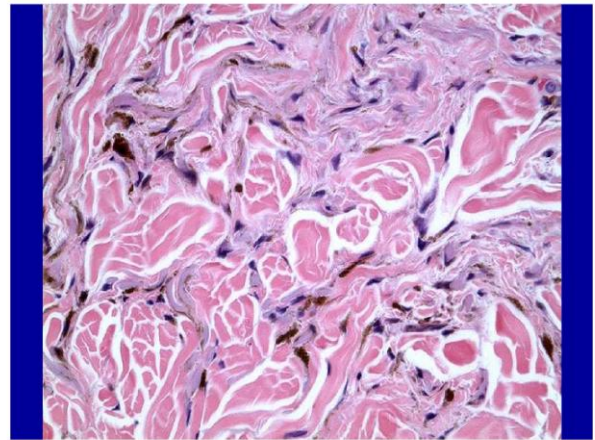
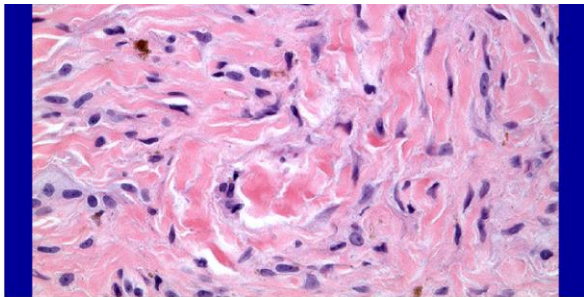
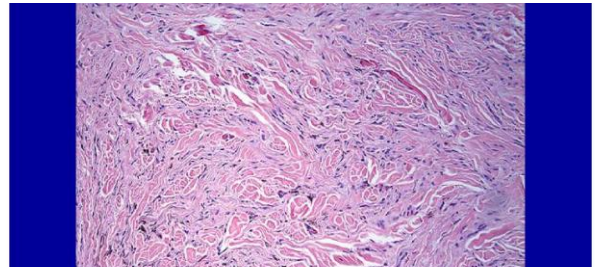
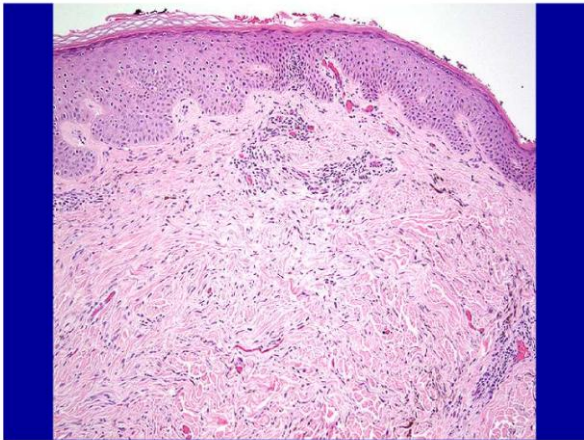
- A) Acanthosis nigricans
- B) Epidermal nevus (non-inflammatory type)
- C) Reticulated seborrheic keratosis
- D) Dowling-Degos disease
- E) Confluent and reticulated papillomatosis of Gougerot and Carteaud



**CASE NO. 18**

Skin-colored firm papule on shoulder. The most appropriate diagnosis is:

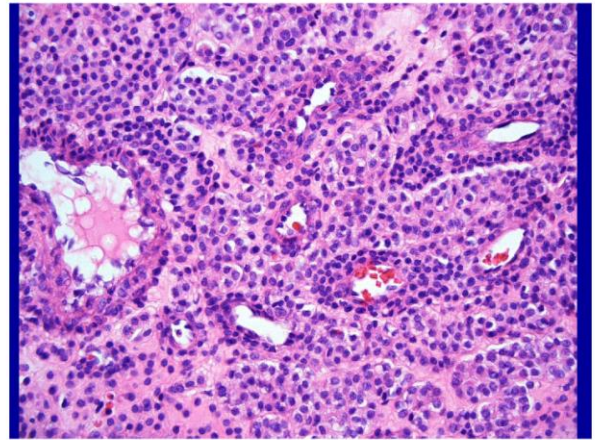
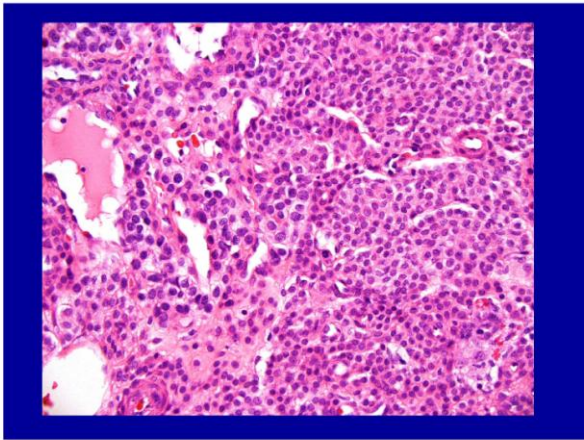
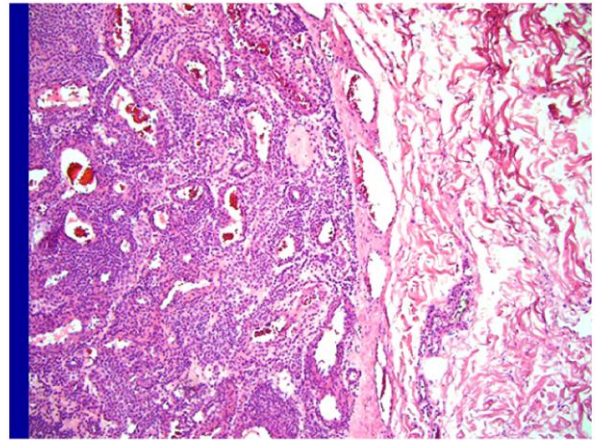
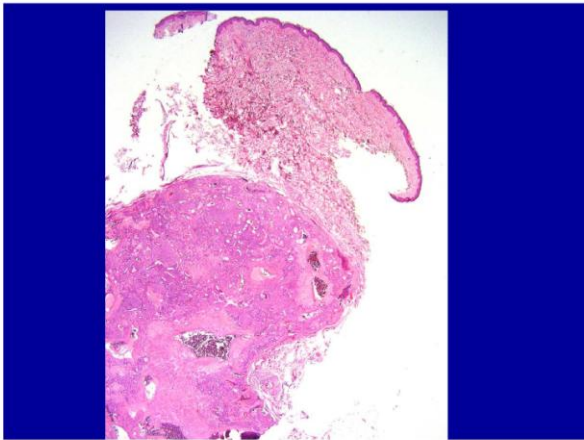
- A) Dermatofibroma
- B) Scar
- C) Desmoplastic melanoma
- D) Pigmented neurofibroma
- E) Hypomelanotic blue nevus



## CASE NO. 19

A 42 year-old man with a bluish-red nodule on the hand. The most likely diagnosis is:

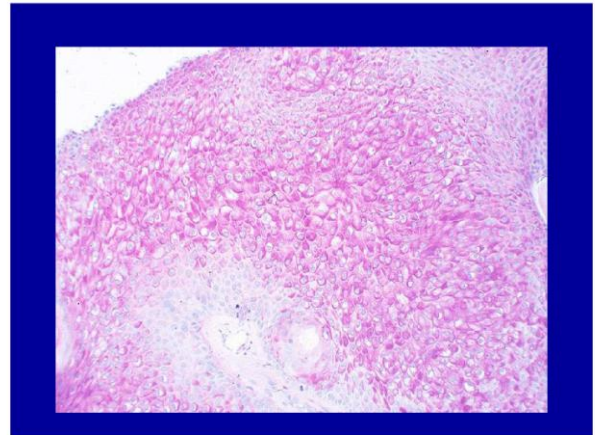
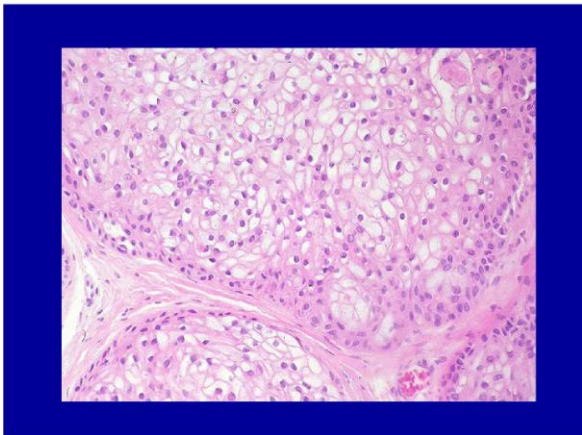
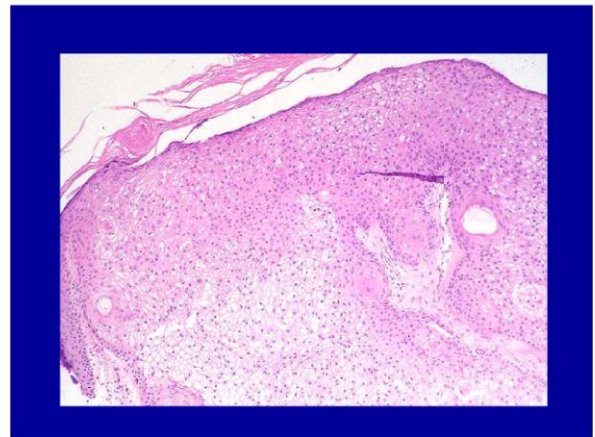
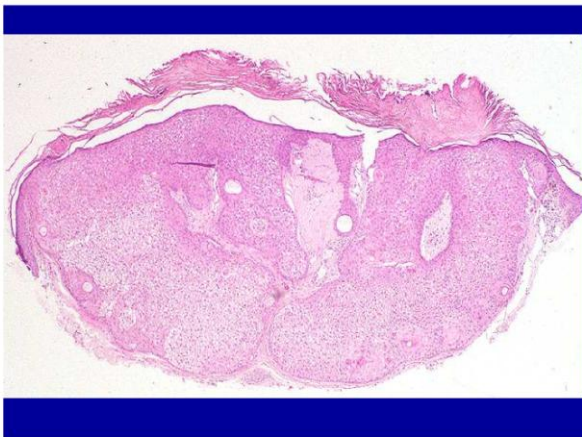- A) Eccrine vascular acrospiroma
- B) Arterio-venous malformation
- C) Solitary mastocytoma
- D) Angioleiomyoma
- E) Glomus tumor



**CASE NO. 20**

18 year-old man with skin-colored papule on face. The most appropriate diagnosis is:

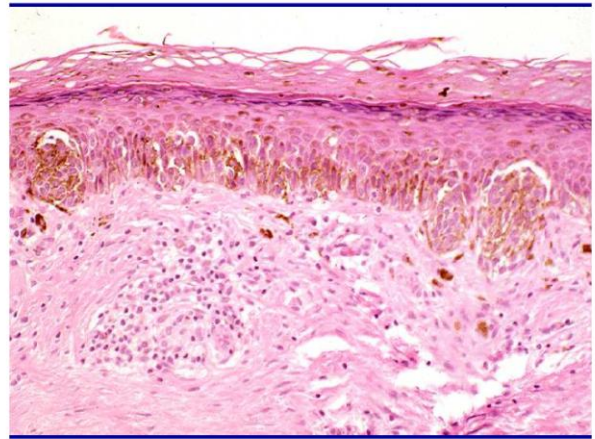
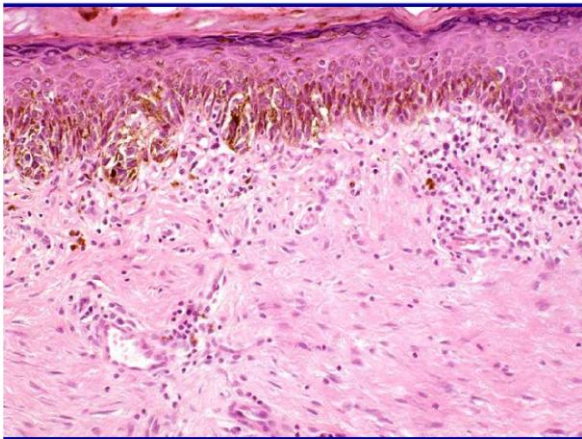
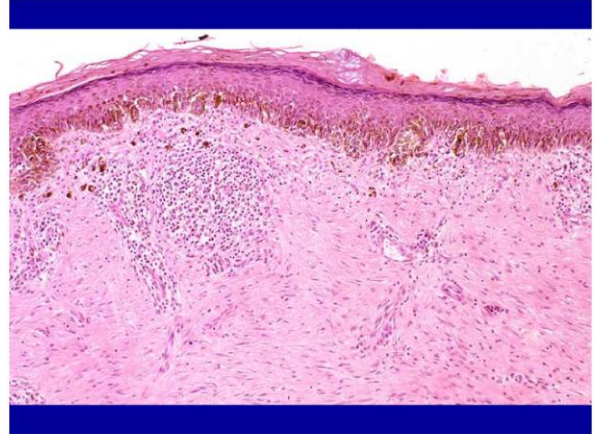
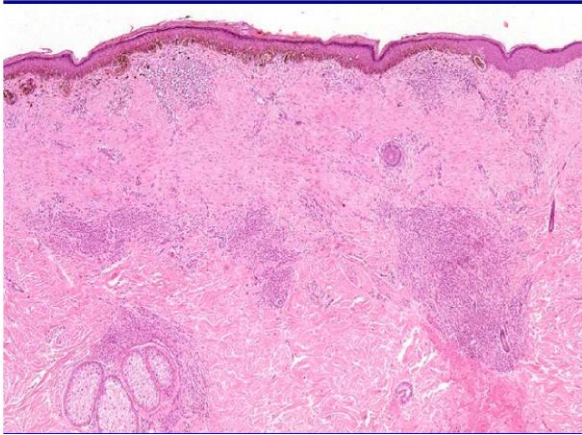
- A) Tumor of the follicular infundibulum
- B) Inverted follicular keratosis
- C) Trichilemmoma
- D) Clear cell hidradenoma
- E) Trichilemmal carcinoma



**CASE NO. 21**

28 year-old man with unevenly pigmented tan-brown macule. The most appropriate diagnosis is:

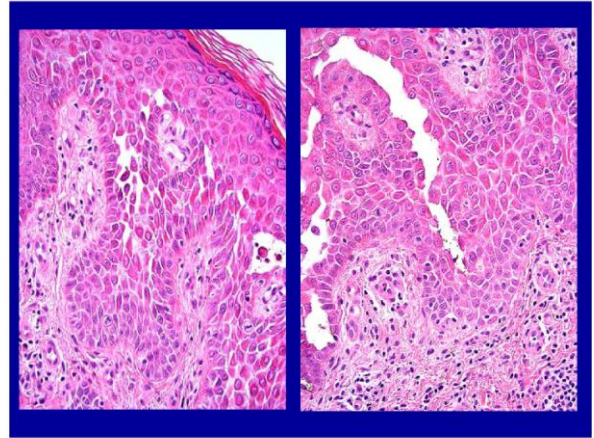
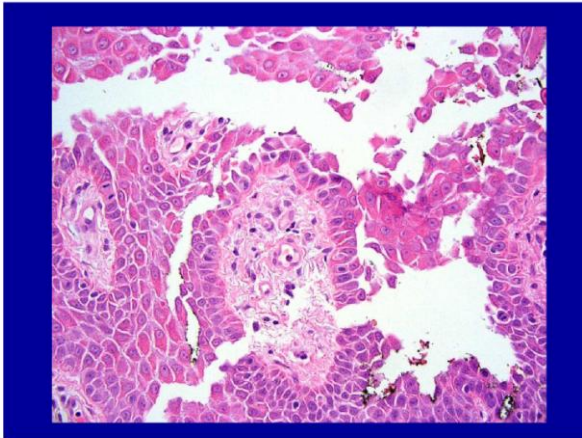
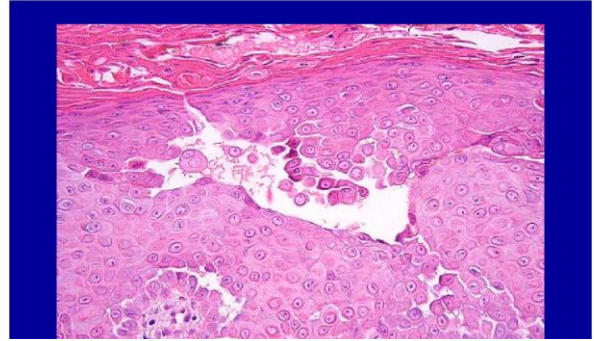
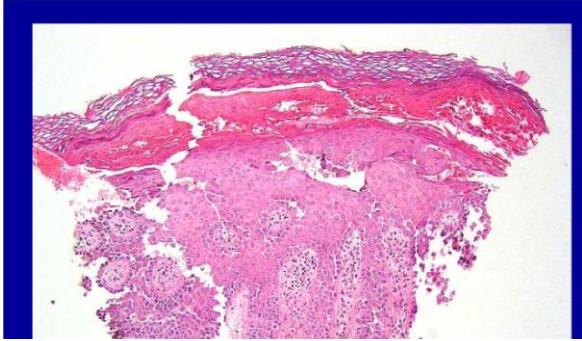
- A) Persistent (recurrent) Clark's nevus
- B) Persistent (recurrent) melanoma
- C) Persistent (recurrent) congenital nevus
- D) Regressing compound nevus
- E) Regressing melanoma



**CASE NO. 22**

A 28 year-old woman with numerous erythematous vesicles. The most appropriate diagnosis is:

- A) Darier's disease (keratosis folliculosis)
- B) Transient acantholytic dermatosis (Grover's disease)
- C) Pemphigus vulgaris
- D) Acute contact allergic dermatitis
- E) Hailey-Hailey disease (familial benign chronic pemphigus)



**CASE NO. 23**

A 52 year-old woman presented with multiple skin-colored firm papules. The most appropriate diagnosis is:

- A) Cutaneous amyloidosis
- B) Sclerotic fibroma
- C) Erythropoietic protoporphyria
- D) Colloid milium
- E) Cutaneous macroglobulinemia

